

## THE FUNCTION OF THE STERNOHYOID MUSCLE IN SPEECH\*

John Ohala and Hajime Hirose

The sternohyoid muscle's participation in regulating the fundamental frequency of phonation has been rather extensively studied via electromyography but relatively little is known about its involvement in other phonetic aspects of speech. Knowledge of this sort is necessary in order to be able to better interpret this muscle's participation in pitch control in speech and in order to let the surgeon know what loss of this often sacrificed muscle may entail.

To date three adult male subjects have been studied via electromyography; one speaker of American English, and two speakers of Japanese. Bipolar wire electrodes were inserted into the muscle at the level of the thyroid cartilage, close to the midline, and roughly parallel to the long axis of the muscle. The two sternohyoid muscles are relatively easy to find and palpate on most subjects and stand out particularly well if the subject, while lying on his back, lifts his head up. The signal was amplified by a DC pre-amplifier designed for EMG and recorded along with the microphone signal on magnetic tape and later on oscillograph paper for detailed examination.

In agreement with others' findings we observed that the sternohyoid is active in both lowering pitch and in achieving extremely high pitch (cf. Figure 1; there is undoubtedly some variation due to intensity of phonation, too, although this was not systematically investigated). In speech, however, the involvement in pitch lowering is most noticeable. This muscle is not invariably active for phonation itself, the presence and degree of activity depending on the pitch (and no doubt, the intensity) of phonation. Not surprisingly, any gesture of speech or non-speech that would most likely require a lowering or fixation of the hyoid bone tended to show an increase

---

\*A paper read at the Semiannual Meeting of the Acoustical Society of Japan, October 15, 1969.

in the activity of this muscle. Likewise, gestures opposite to this tended to show little or no activity in this muscle. Thus, specifically, jaw opening, tongue lowering, and tongue retraction all typically involved participation of the sternohyoid. Jaw opening probably involves fixation of the hyoid bone since the digastric muscle, which is chiefly responsible for opening the jaw, loops around the hyoid bone and would tend to pull it upwards when it contracts if this movement were not opposed by the sternohyoid. The sternohyoid tends to be inhibited during jaw closing, tongue protrusion, and tongue raising. Some of these patterns are present in Figure 2a which shows the microphone signal and the EMG signal from the sternohyoid during the word [atari] as pronounced by one of the Japanese speakers. From left to right, one can see the increase in activity for initial jaw opening for [a], cessation of activity for tongue tip raising and jaw raising for [t], followed by activation for jaw opening for the second [a], followed again by a sudden decrease in activity for the flap [r] and for the [i], followed, finally, by some low-level "baseline" activity. Pitch did not fall at the end of this utterance so there is no remarkable change in activity associated with pitch control in this sample. There was some individual variation in these patterns. In one subject there was only very slight participation of the sternohyoid in segmental gestures such as jaw opening compared to its quite evident activation for such non-speech gestures as head raising from a face-up, lying-down position.




Figure 1. Musical scale from extreme low pitch (left) to high pitch (right) in chest register with the jaw closed. Top trace: EMG signal from sternohyoid muscle; bottom trace: microphone signal.

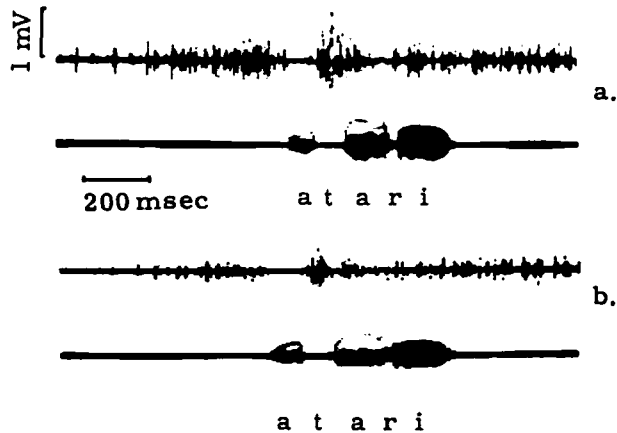


Figure 2. Two renditions of [atari], (a) with jaw free to move, and (b) with jaw clenched. Top trace: EMG from sternohyoid; bottom trace: microphone signal.

Strictly speaking, it is not possible to invariably associate these muscle action patterns with individual phonemes because the pattern of activation depends highly on contextual factors. Thus we might be tempted to characterize the phoneme /a/ by a certain pattern of increased activity such as is found for the initial /a/ in the lower figure. But we find that the precise pattern varies considerably depending on the presence and nature of any preceding phonemes (as evidenced by the discharge for the second /a/), and the pattern is even more dependent on whether the jaw is used or not as is shown by Figure 2b. This point is even more evident when we consider that some of these gestures, even those typically involving opposite modes of activation of the sternohyoid, can occur simultaneously, e. g., pitch lowering can certainly occur during tongue raising. The muscle of course cannot do two opposite things at the same time; one gesture predominates over the particular muscle and it follows the dictates of that gesture. This merely indicates, as has long been known and which has even been given sophisticated theoretical treatment (Bernstein 1967), that the identity and characteristics of complex gestures such as jaw opening, tongue raising, head raising, etc., do not lie in the individual muscles which are (sometimes) used to execute the gestures.

Muscle X may or may not be used depending on its current availability and usefulness. Surgical practice has provided constant evidence that certain isolated muscles can be safely eliminated if necessary without seriously affecting a patient's total gestural repertory. This is particularly true of areas such as the neck which have a highly redundant supply of muscles; less true of other less redundant anatomical systems. However it seems that this fact has occasionally been overlooked by some workers in speech who in the past decade have sought invariant patterns of muscle action potentials for certain phonemes. The situation in speech is somewhat analogous to that which exists in handwriting. As Bernstein pointed out, whether we write large characters on a vertical blackboard or small characters on a horizontally-placed piece of paper, the characters are somehow the same even though they were produced by wholly different sets of muscles. In speech it is undoubtedly the modulations of the sound wave which are important and necessary for a word to maintain its identity. Thus we would count the two renditions of [atari], above as the same word because both utterances incorporate the same sequence of acoustic modulations. They do not, however, involve the same pattern of activation in the sternohyoid or, no doubt, other muscles. In a more extreme case, a subject speaking while lying on his stomach and elevating his head usually exhibits no activity at all in his sternohyoid.

Ultimately we want to be able to completely account for the observed EMG patterns both qualitatively and quantitatively. Towards this perhaps distant goal, future studies will involve measuring movements of the mandible, hyoid bone and larynx simultaneously with sampling EMG from the sternohyoid, as well as from other muscles linked to the hyoid bone.

#### R e f e r e n c e

N. Bernstein, The Co-ordination and Regulation of Movements, Oxford: Pergamon Press, 1967.