

Significance of combined use of fiberscopy and  
fluorovideoradiography in cleft palate speech

Nobuhiko Isshiki and Michio Kawano\*

Cleft palate speech is usually considered to consist of two factors : velopharyngeal incompetence and articulatory disorders. As to the former, a number of diagnostic means are now available. Among those, velopharyngofiberscopy seems to be most popular and clinically significant.

On the other hand, as to the faulty articulations which are specific for cleft palate are mostly assessed on the auditory impression by experienced speech therapist. This rather subjective approach to the complicated problem of faulty articulation sometime has led to a confusion in terminology and understanding the underlying mechanism for the faulty articulation.

Taking glottal stop and omission for instance, there seems to be no unanimously accepted criteria to judge whether a given speech sound is glottal stop or omission. The terminology "pharyngeal fricative" has been used to designate faulty fricative sound, of which the articulatory place is assumed to be in the pharyngeal region on the basis of sound impression without objective finding.

Our recent study showed that this kind of approach on the basis of auditory judgement can sometimes be quite misleading; What was considered as pharyngeal fricative was found to be laryngeal fricative by the combined use of fiberscopy and fluorovideoradiography. These diagnostic means are further capable of disclosing: a) exact site of articulation b) interaction between articulatory movement, especially of the tongue, and the velopharyngeal function.

This paper describes two advantageous aspects with the combined use of fiberscopy and fluorovideoscopy.

#### Method and Material

##### Fiberscopy:

A flexible fiberscope 4mm in external diameter is inserted through the nostril to observe the velopharyngeal dynamic movement during articulation. The picture is recorded on videotape so as to permit later repeated observation and analysis (Fig. 1).

---

Department of Plastic Surgery and \* Otolaryngology,  
Kyoto University

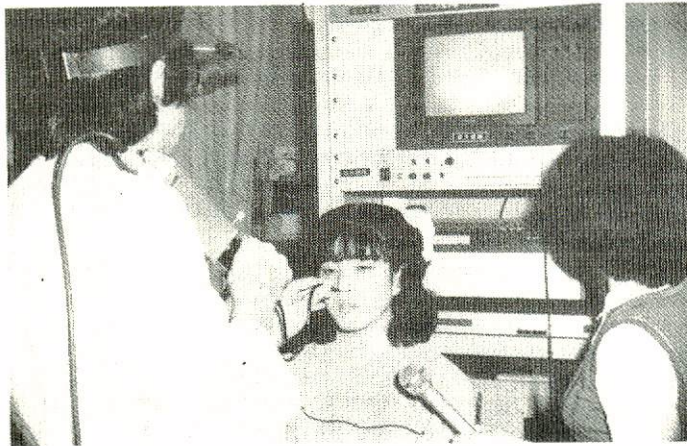

Fig. 1.: A flexible fiberscope 4 mm in external diameter is inserted through the nostril for examining the velopharyngeal function. The picture is recorded on videotape.




Fig. 2.: Fluorovideoradiography is carried out in two directions; dorsoventral direction for viewing the lateral wall movement, lateral direction for velar and lingual movement.

### Fluorovideoradiography:

Radiopaque substance is instilled through the nostril and from the mouth to coat the velopharynx and the vocal tract. Fluorovideoradiography is performed during utterance of selected words or passage in two directions; dorso-ventral and lateral. The speech is simultaneously recorded on videotape (Fig. 2).

#### 1. Locating the exact place for faulty articulation.

A patient with operated cleft palate had an apparent faulty articulation of /S/ sounds. He could produce them with the mouth open (Fig. 3). At first, we thought it must be pharyngeal fricative. A thorough fiberoptic examination showed that the site of articulation was at the larynx especially at the narrow space between the epiglottis and the arytenoid region (Fig. 4). Fluorovideoradiography further corroborated that the articulatory site was not in the pharynx but at the airway in the larynx (Fig. 5).

#### 2. Detection of the coarticulatory relation among the tongue, velopharynx and larynx (Fig. 6).

Under fluorovideoradiography, the above-mentioned patient received speech therapy to correct the laryngeal fricative with the following instructions;

- a) produce /s/ sound with whisper,
- b) try to thrust the tongue anteriorly under the visual guidance of the fluorovideoscopy.

What was extremely interesting in this patient was that the velopharynx started closing on production/s/ when it was produced at the correct site between the tip of the tongue and the tooth. This is an example of improved velopharyngeal function spontaneously obtained by correcting faulty articulation.

We have experienced a number of cases where incompetent velopharynx becomes competent auditorily as well as visually on the videoscreen, as soon as faulty manner of articulation is corrected. Fig. 7 illustrates velopharyngeal incompetence for faulty /s/, which was corrected with the use of whispered voice, with attendant velopharyngeal competence (Fig. 8).

Fluorovideoradiography can demonstrate the process in which the faulty articulatory movement is being corrected in response to a certain instruction for articulation, i.g., whisper. This information is of critical importance in studying how a certain speech therapy works on articulation. Furthermore, it helps patient learn a correct articulation through the visual feedback system.

In short, fluorovideoscopy together with fiberoptic contributes greatly to make speech therapy for cleft palate speech more effective. Fiberoptic alone, though quite useful for diagnosing velopharyngeal function, can not provide any

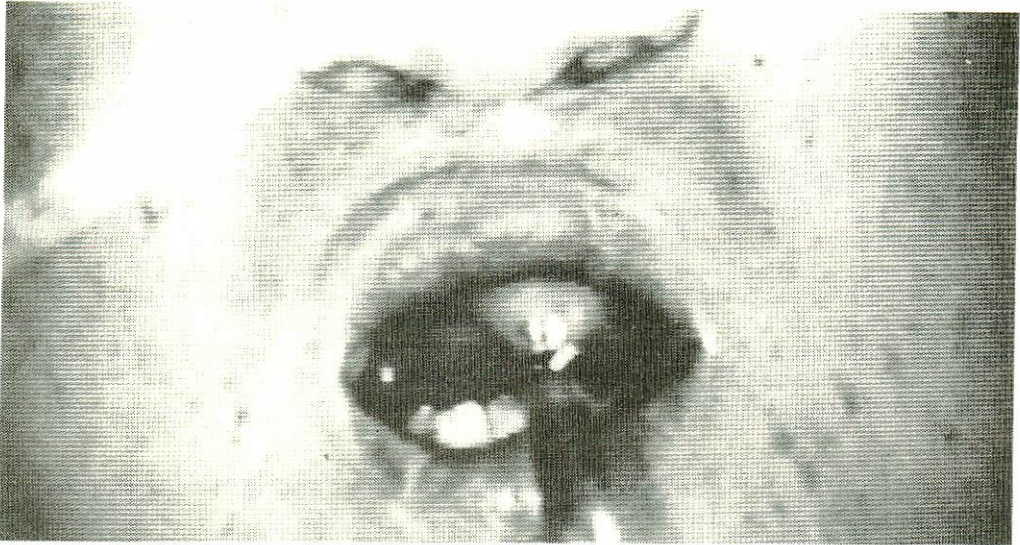

Fig. 3.: A patient with repaired cleft produces /s/ with the mouth open and the tongue pressed down.

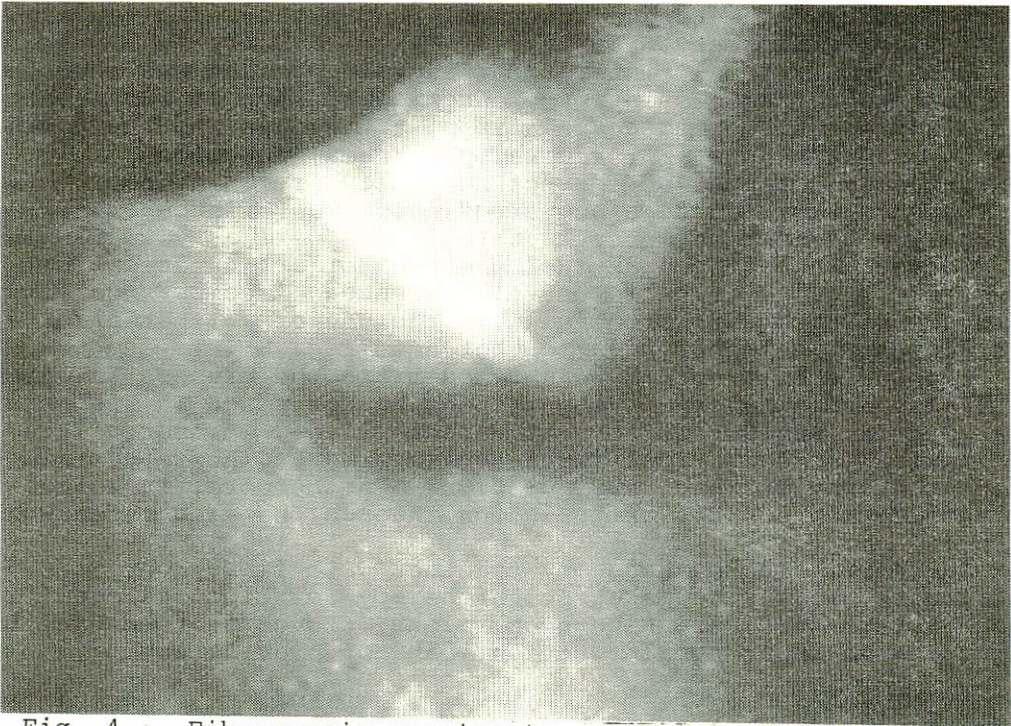


Fig. 4.: Fiberscopic examination revealed velopharyngeal opening, and the site of fricative sound production to be at the larynx. The arytenoids are pulled antero cranial direction toward the epiglottis, covering the vocal cords during production of /su/.

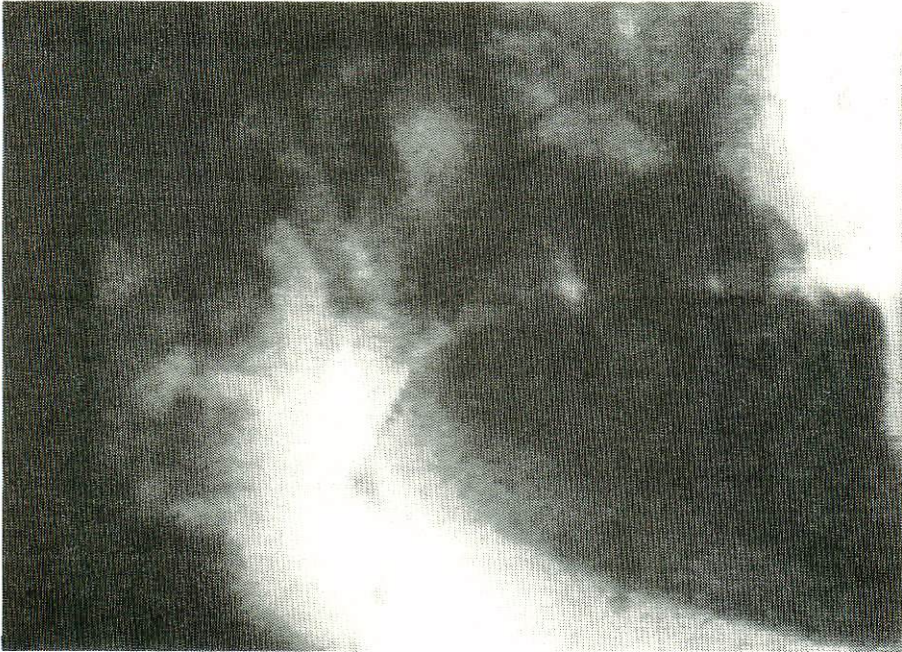


Fig. 5.: Fluorovideoradiography reveals velopharyngeal incompetence and abnormal approximation of the epiglottis and arytenoids.

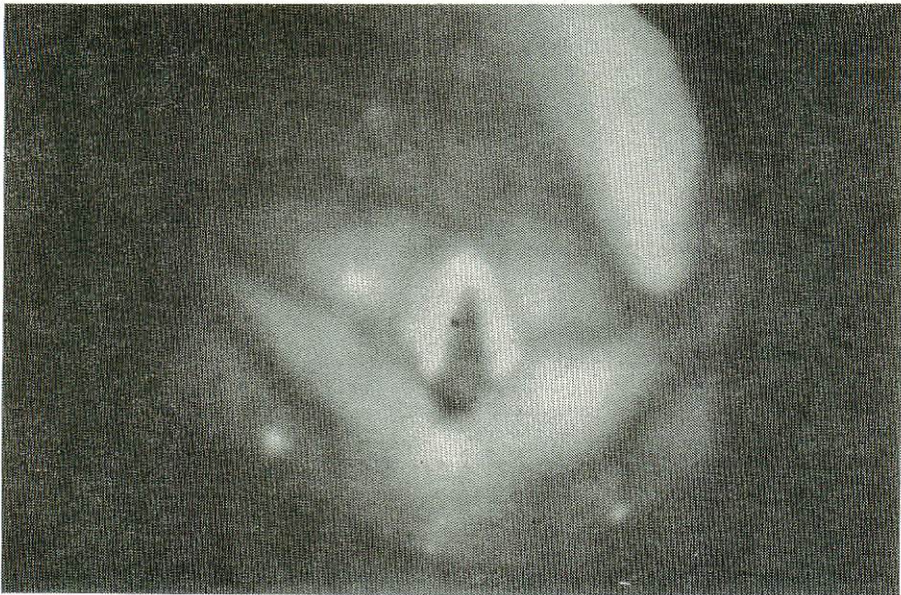


Fig. 6.: After speech therapy for laryngeal fricative, the vocal cords became visible during production of /su/.

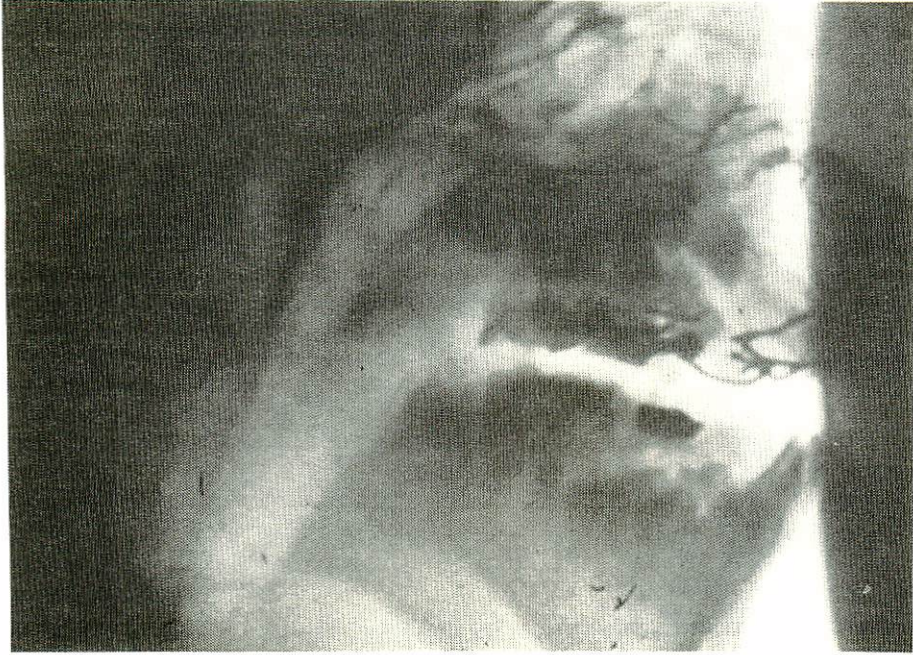

Fig. 7.: Velopharyngeal incompetence during production of / i/.

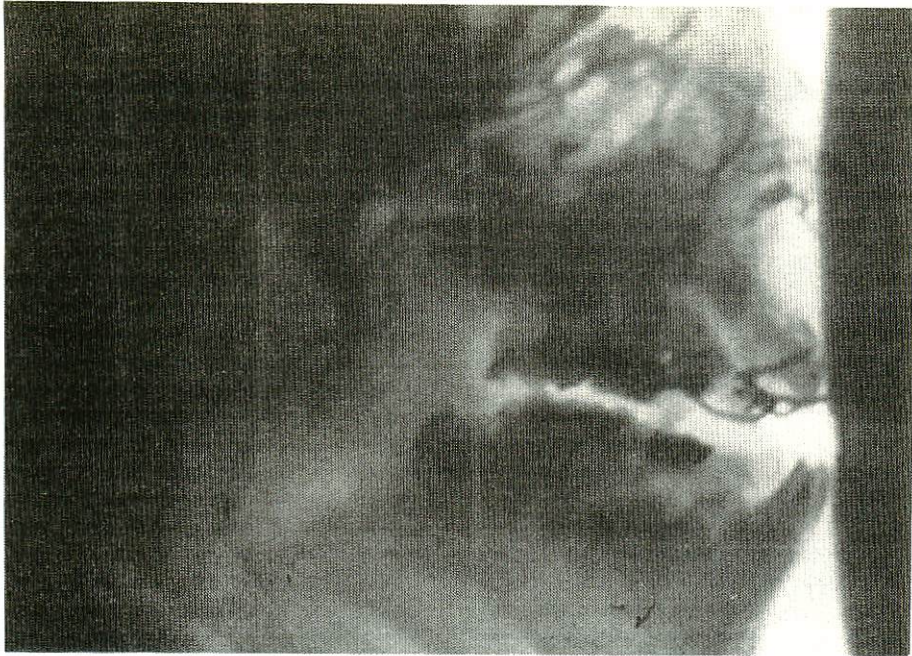

Fig.8.: Velopharyngeal competence during production of / i/, after speech therapy. Note the change in position of the tongue and the mouth opening.

information as to the coarticulatory relation with the other articulatory organs.

Fluorovideoscopy should be carried out most carefully not to exceed the safety dosis of radiation. The X-ray exposure and indication for this examination should be strictly limited after thorough examination of the condition of the patient and the necessity of the test.

#### Conclusion

Combined use of fiberscopy and fluorovideoscopy can provide various useful information as to a) exact place of the faulty articulation, b) detailed pattern of inconsistent velopharyngeal function, c) the process of changing articulatory movement which is induced by speech therapy, and d) relation between velopharyngeal function and faulty articulation.

All the above information greatly facilitates speech therapy for cleft palate speech. It should be done with utmost care, though, due to possible adverse effects of radiation.

#### References

1. Albery EH, Bennet JA, Pigott RW and Simmons RM. : The result of 100 operations for velopharyngeal incompetence-selected on the findings of endoscopic and radiological examination. *British Journal of Plastic Surgery*. 35:118-126, 1982.
2. Glaser, ER. : The dynamics of Passavant's ridge in subjects with and without velopharyngeal insufficiency-a multi-view videofluoroscopic study. *Cleft Palate J*. 1:24-33, 1979.
3. Henningsson, GE. and Isbeg, AM. : Velopharyngeal movement patterns in patients alternating between oral and glottal articulation: a clinical and cinradiographical study. *Cleft Palate Journal*.23:1-9, 1986.
4. Isshiki N, Honjo I and Morimoto M. : Cineradiographic analysis of movement of the lateral pharyngeal wall. *Plastic and Reconstructive Surgery*.44:357-363, 1969.
5. Kawano M, Isshiki N, Harita Y, et al : Treatment and result of slight velopharyngeal incompetence. *Studia Phonologica* 17:15-26, 1983.
6. Kawano M, Isshiki N, Hagio F, et al : Basic guideline for rehabilitation of patients with cleft palate. *Studia Phonologica* 16:26-36, 1982.
7. Kawano M, Isshiki N, Harita Y, and Tanokuchi F. : Laryngeal fricative in cleft palate speech. *Acta Otolaryngeal*.419:180-188, 1985.
8. Pigott RW. : Nasoendoscopy in the diagnosis of velopharyngeal incompetence. *Plastic and Reconstructive Surgery*.43:141-147, 1969.
9. Pigott RW. : The nasoendoscopic appearance of normal palatopharyngeal valve. *Plastic and Reconstructive Surgery*.43:19-24, 1969.
10. Schneider, E. and Shpritzen, RJ. : A survey of speech pathologists, current trends in the diagnosis and management of velopharyngeal insufficiency. *Cleft Palate Journal*.17:249-253, 1980.

11. Shelton, RL, Chisum, L and Youngstrom KA. : Effect of articulation therapy on palate-pharyngeal closure, movement of the pharyngeal wall, and tongue posture. Cleft Palate Journal. 6:440-448, 1969.
12. Shprintzen RJ, Lencione RM, McCall GN and Skolnick ML. : A three dimensional cinefluoroscopic analysis of velopharyngeal closure during speech and non-speech activities in normal. Cleft Palate Journal. 11:412-428, 1974.
13. Skolnic ML. : Videofluoroscopic examination of the velopharyngeal portal during phonation in lateral and base projection-A new technique for studying the mechanics of closure. Cleft Palate Journal.7:803-816, 1970.
14. Skolnick ML, McCall GN and Barnes M. : The sphincteric mechanism of velopharyngeal closure. Cleft Palate Journal. 10:286-305, 1973.
15. Shaw RE, Folkins JW and Kuehn DP. : Comparison of method for measuring velar position from lateral-view cineradiography. Cleft Palate Journal.17:326-329, 1980.
16. Zwitman DH, Sonderman JC and Ward PH. : Variations in velopharyngeal closure by endoscopy. JSHD.39:366-372, 1974. mechanics of closure. Cleft Palate Journal.